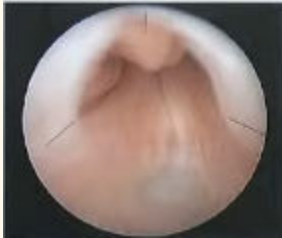

# NEET PG 2024 Question Paper Shift 2

---


**Ques 1.**What is the management of the endoscopic finding given in an image ?



- a. Stenting
- b. Balloon dilatation.
- c. Fulguration
- d. Internal urethrotomy

**Ans. c**

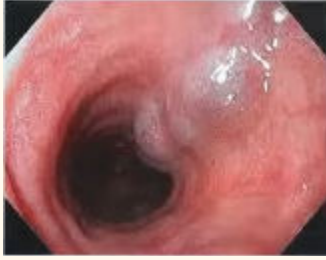**Ques 2.** A young patient presented with recurrent colicky abdominal pain, urine microscopy found to have crystals and RBC, what is the diagnosis ?



- a. Oxalate stone
- b. PKD
- c. Cystine stones
- d. Glomerulonephritis

**Ans. c**

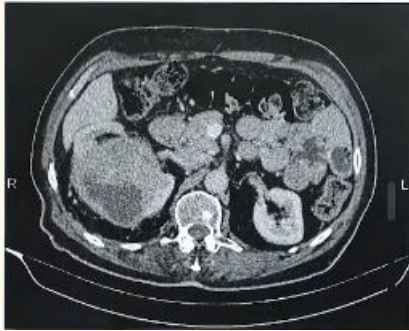**Ques 3.** Identify the image given in UGIE



- a. Barrets esophagus
- b. Esophageal varices
- c. Gastric esrosion

**Ans. b**

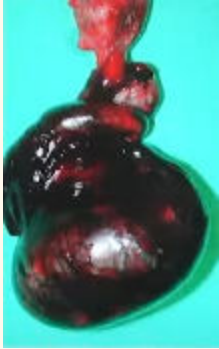
**Ques 4. Identify the disease shown in the image**



- a. PKD
- b. Renal cyst
- c. Medullary sponge kidney
- d. PUJ obstruction

**Ans. b**

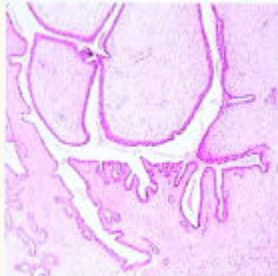
**Ques 5. Q. A 12 years old child presented with sudden severe onset of scrotal najn after an history of trauma 6 hours before. Intra operative image is given what is the likely diagnosis?**



- a. Torsion testis with gangrene
- b. Testicular hematoma
- c. Torsion testis
- d. Gangrene of testis

Ans. a

Ques 6. Q. A 40 years old female with lump in breast measuring 5 X 6 cm with HPE given in the image, what is the likely diagnosis ?



- a. Phyllodes tumour
- b. Fibroadenoma
- c. Breast carcinoma

Ans. a

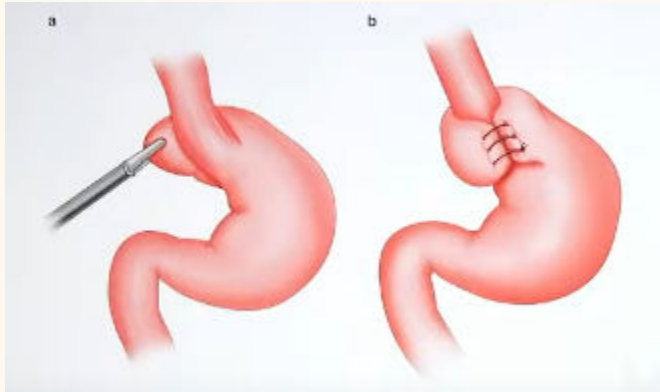
Ques 7. What is the negative pressure in VAC dressing

- a. 60-90 mmHg
- b. 90-100 mmHg
- c. 120-130 mmHg

d. 130-150 mmHg

Ans. c

Ques 8. . Identify the surgery shown in the image



a. Nissens fundoplication

b. Dor

Ans. a

Ques 9. Identify the structure marked in the intra operative image of congenital inguinal hernia ?

a. Femoral vein

b. Obturator vein

c. Testicular vein

d. Inferior epigastric vein

Ans. c

Ques 10. What biopsy would you take from the lesion shown

a. Excisional

b. Incisional

c. Edge

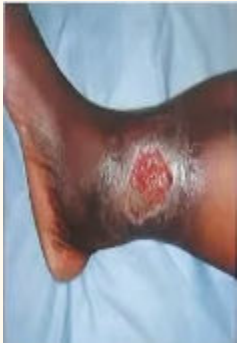**Ans. c**

**Ques 11. How does skin graft derives its nutrition on day 3**

- a. Plasma imbibition**
- b. Inosculation**
- c. Neovascularization**
- d. None**

**Ans. b**

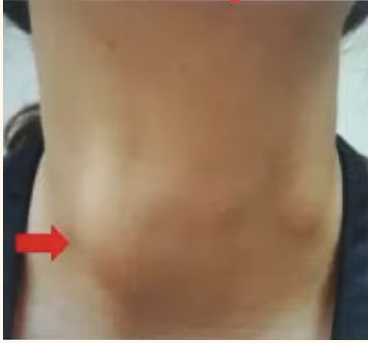**Ques 12. Identify the ulcer**



- a. Arterial**
- b. Venous**
- c. Trophic**
- d. Diabetic foot ulcer**

**Ans. b**

**Ques 13. A 30 years old female presented with the swelling in neck, what is the next step in evaluation ?**



- a. 1131
- b. FNAC
- c. TSII & T4
- d. FSH

**Ans. c**

**Ques 14. Identify the drain in the image**



- a. ROMOVAC
- b. JACKSON PRATT
- c. CORRUGATE
- d. PENROSE

**Ans. a**

**Ques 15. A 5-year-old girl was washing her doll with shampoo containing a chemical Rotenone. Her mother notice her in unconscious state. Which of the following Complex is inhibited by the above-mentioned chemical?**

- A. NADH Dehydrogenase**
- B. Succinate DH**
- C. Cytochrome C**
- D. Cytochrome oxidase**

**Ans. A**

**Ques 16. A patient present with dilated cardiomyopathy on x ray and hypoglycemia, floppy baby, hypotonia, hepatomegaly. What is most likely diagnosis?**

- A. Pompe's disease**
- B. Von Gierke's disease**
- C. Ebstein anomaly**

**Ans. A**

**Ques 17. A 15-year-old child with difficulty in exercise, affected oxidation of long chain fatty acids and biopsy muscle shows fat vacuoles. Which of the following is the diagnosis?**

- A. Carnitine deficiency**
- B. FA synthase defect**
- C. LPL defect**
- D. LDL defect**

**Ans. A**

**Ques 18. A Farmer was on maize as staple diet develops rash on face, neck and hand. Which of the following vitamin should be given in the treatment?**

- A. Niacin
- B. Thiamine

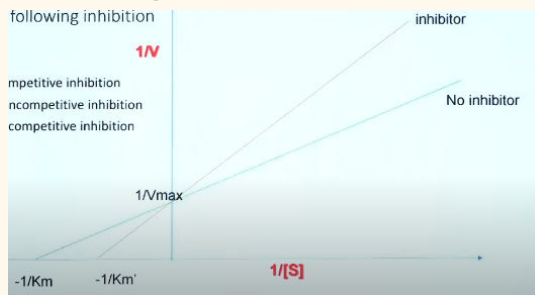
Ans. A

Ques 19. A patient develops mouth ulcers on treatment with Methotrexate. Which of the following will decrease with this drug?

- A. UMP
- B. TMP
- C. CMP

Ans. B

Ques 20. Increased  $K_m$  and unchanged  $V_{max}$  is seen in which of the following inhibition



- A. Competitive inhibition
- B. Noncompetitive inhibition
- C. Uncompetitive inhibition

Ans. A

Ques 21. A drug is given for the treatment of hyperlipidemia. Facial flushing was noted. Which of the following drug causes this side effect?

Ans. Nicotinic acid



**Ques 22. Increased chylomicron, lipemic serum is seen in.**

**Ans. Lipoprotein lipase deficiency**

**Ques 23. Which micronutrient deficiency causes anemia, gum bleeding and x ray changes - White frankel line?**

- A. Copper**
- B. Iron**
- C. Zinc**

**Ans. B**

**Ques 24. Which of the following enzyme is deficient in patient with Phenylketonuria if phenylalanine hydroxylase level is normal**

**Ans. Dihydrobiopterine reductase**

**Ques 25. A tall stature, long digits, long arm span and sublaxation of lens is seen in which of the following defect**

- A. Fibrillin 1**
- B. Collagen**

**Ans. A**

**Ques 26. A male patient with pallor, weakness and easy fatigability. His blood report shows MCV 53, TIBC- Increased. What is your diagnosis?**

**Ans. Iron deficiency anemia**

**Ques 27. Which of the following is methanol poisoning derivatives?**

- A. Formic acid+ Lactic acid**
- B. Acetic acid**

**Ans. A**